

Phacoemulsification Combined with Intravitreal Triamcinolone Acetonide Injection in Cataract Patients with Diabetic Macular Edema

¹K.G. Mohamed, ¹T.T.Soliman, ¹A.E.Mohamed, ¹W.S.Abusaif
¹Ophthalmology , Dept., Faculty of Medicine, Benha Univ., Benha, Egypt
E-Mail:ahmed2356@gmail.com

Abstract

To assess the safety and efficiency of combined phacoemulsification surgery and intravitreal triamcinolone (IVTA) injection in patients with cataract and diabetic macular edema. This study included “40 patients” having immature senile cataract with clinically significant macular edema. Phacoemulsification was done with posterior chamber intraocular lens implantation and intravitreal triamcinolone injection. Patients were followed up on day 1, day 3 then weekly for 1 month, and thereafter monthly for 6 months postoperatively. Best corrected visual acuity (BCVA) & central macular thickness (CMT), and intraocular pressure (IOP) were recorded. All patients completed 6 months of follow up. Mean BCVA showed statistically significant improvement from a baseline of 0.08 ± 0.05 decimal to 0.3 ± 0.13 decimal at 3 months and 0.35 ± 0.16 decimal at 6 months. Mean CMT decreased significantly from a baseline of $504.85 \pm 109.05 \mu\text{m}$ to $341.10 \pm 75.35 \mu\text{m}$ at 3 months and $322.05 \pm 87.40 \mu\text{m}$ at 6 months. IOP was elevated in 6 patients (15%) > 21 mmHg one month after injection but, all brought under control with anti-glaucoma medications. No injection- or surgery-related complications were encountered. Phacoemulsification with concurrent 4 mg IVTA injection appears to be a safe and effective option for managing diabetics with cataract and CSMO.

Keywords: Phacoemulsification; intravitreal triamcinolone; cataract; diabetic macular edema.

1. Introduction

Macular edema is the most frequent cause of visual loss among patients with diabetic retinopathy ⁽¹⁾. It is caused by breakdown of the inner blood retinal barrier and increase vascular permeability due to release of inflammatory mediators such as Prostaglandins and the Vascular Endothelium Growth Factors (VEGF) ⁽²⁾.

Fluorescein angiography and Optical Coherence Tomography (OCT) are helpful in establishing or confirming the diagnosis of macular oedema in addition to evaluating the degree of vascular leakage and the macular thickness ⁽³⁾.

Cataract surgery is an inflammatory insult to the eye, and the risk of macular thickening after uncomplicated phacoemulsification may increase in the presence of ocular or systemic diseases such as uveitis or diabetes ⁽⁴⁾. The severity of retinopathy may have an influence on the visual outcomes after uncomplicated phacoemulsification in patients with diabetes. Unstable DR with clinically significant macular edema at the time of phacoemulsification surgery tends to worsen postoperative macular edema ⁽⁵⁾.

Corticosteroids are known for ability to inhibit the arachidonic pathway ⁽⁶⁾. Triamcinolone acetonide is a corticosteroid that has been used as intravitreal injections for the treatment of refractory diabetic macular edema. Intravitreal injection of Triamcinolone acetonide is efficient in decreasing macular edema with a transient effect lasting up to 6 months ⁽⁷⁾. Combining triamcinolone acetonide injection with cataract surgery helps in controlling diabetic macular edema in one procedure ⁽⁸⁾.

2. The aim of the study

is to evaluate the safety and efficacy of phacoemulsification combined with intravitreal Triamcinolone acetonide injection in cataract patients with diabetic macular edema.

3. Subjects & Methods

This was a prospective interventional study that included 40 eyes of 32 patients evaluated at the outpatient clinic of the Ophthalmology Department, Benha University Hospital, and diagnosed with immature senile cataract and non-proliferative diabetic retinopathy with macular edema. Patients were subjected to phacoemulsification with posterior chamber intraocular lens implantation and intravitreal triamcinolone injection at the end of surgery, then followed-up for 6 months after surgery.

All examinations were performed according to a protocol that complied with the tenets of the Declaration of Helsinki and that was approved by the Institutional Review Board and Ethics Committee of Benha University. All patients received a thorough explanation of the study design and aims, and were provided with written informed consent.

Exclusion criteria included previous ocular trauma and ocular surgery, previous laser photocoagulation or intravitreal injections, any significant media opacity other than cataract, proliferative diabetic retinopathy, glaucomatous patients, macular edema caused by tractional element or any causes other than diabetic retinopathy and cases with complicated phacoemulsification with vitreous herniation due to posterior capsule rupture or zonular dialysis.

Pre-operative evaluation:

All patients were subjected to the following:

- History taking (age, gender, occupation, past-medical history, past-surgical history & ocular history)
- Best-corrected visual acuity was assessed
- Slit lamp examination to assess the density of cataract.
- Indirect ophthalmoscopy: Fundus examination was done.
- Intraocular pressure (IOP) measurement.
- Investigations:
 - Laboratory: -complete blood count (CBC), fasting blood sugar, HbA1c
 - Fundus Fluorescein angiography (FFA) to detect signs of vascular leakage as well as ischemia in patients who demonstrate clinically visible maculopathy.
 - Optical Coherence Tomography (OCT) to document macular thickness preoperatively: In all patients, 3D macula scan protocol 512x128 (128 horizontal scan lines comprised of 512 A-scans) over a 6-mm² area centered on the fovea was conducted using Topcon 3D OCT-2000 FA, JAPAN "version 8.30".

Operative procedure:

Uncomplicated Phacoemulsification and intracapsular intraocular lens implantation was performed (single-piece foldable hydrophilic acrylic IOL). At the end of the cataract surgery, 4mg of triamcinolone acetonide (Epirefan 40mg/1 ml vial ,Eipico,EGYPT) in 0.1 ml injected at a site 3.5mm posterior to the inferotemporal limbus.

Postoperative evaluation:

- Patients followed up on day 1, day 3, then weekly for 1 month, and thereafter monthly for 6 months postoperatively.
- (BCVA) and IOP were documented in each visit.
- Macular edema was monitored by OCT and Fluorescein angiography at 3months and 6 months.

4. Results

The study included 40 eyes of 32 diabetic patients [18 males (56.25%) and 14 females (43.75%)] whose age ranged from 42 to 71 years (mean = 57 years ± 7). The right eye was affected in 19 eyes (47.5%) while the left was affected in 21 eyes (52.5%). The mean FBS of

the whole group was 286.0 ± 7.23 mg/dl while the mean HbA1c was 7.65 ± 0.98, as tabulated in (Table 1). IOP was elevated in 6 patients above 21 mmHg one month after injection, but all brought under control with anti-glaucoma medications. The mean preoperative IOP was 13.70 ± 1.82 (mmHg). One month after injection, the mean IOP significantly elevated to 16.40 ± 4.53(mmHg), however, at the 3rd month, it was significantly reduced to 14.30 ± 1.93 (mmHg) to be non-significant from the preoperative level. The level of IOP continued to be stable at 14.30 ± 1.87 (mmHg) till the 6th postoperative month, as tabulated in (Table 2), and illustrated in (Fig.1).

The obtained results showed a significant decrease in the central macular thickness (CMT) postoperatively up to the 3rd month in all eyes of the study except in two eyes where the reduction of CMT wasn't that significant. At the 6th month postoperatively, ten cases (25%) again developed an increase in the central macular thickness (CMT). Mean CMT decreased significantly from a baseline of 504.85 ± 109.05 µm to 341.10 ± 75.35 µm at 3 months and 322.05 ± 87.40 µm at 6 months, as tabulated in (Table 3) and illustrated in (Fig.2).

Assessment of visual acuity during the 6 months follow up showed a significant improvement in VA postoperatively in all patients by more than 2 lines in snellen chart at 3 months except in 6 eyes where the improvement of VA was minimal . at the 6th month, of total, 24 eyes showed a significant improvement in VA by more than 2 lines in snellen chart. Mean BCVA showed statistically significant improvement from a baseline of 0.08 ± 0.05 decimal to 0.3 ± 0.13 decimal at 3 months and 0.35 ± 0.16 decimal at 6 months, as tabulated in (Table 4) and illustrated in (Fig.3).

HbA1c had significant negative correlation with the 6th month BCVA, but significant positive correlation with the 6th month CMT, as tabulated in (Table 5).

An Example of a patient's serial OCT macula & FFA is shown in (Fig. 4-7).

Table (1) Patients' characteristics:

Variable	Values
Gender:	18 (56.25%)
Male	14 (43.75%)
Female	
Eye laterality (No.)	
OD	19 (47.5%)
OS	21 (52.5%)
Age in years (mean± SD, range)	57 ± 7, 42-71
Fasting blood sugar (mg/dl) (mean± SD, range)	286.0 ± 84.68, 145.0-500.0
HbA1c (mean± SD, range)	7.65 ± 0.98, 6.0-9.80

Table (2) IOP (mmHg) of the patients at all-time measures:

Variable	Preop	1 st month	3 rd m	6 th month	F test	P value	Post Hoc
IOP (mmHg)	13.70 ± 1.82	16.40 ± 4.53	14.20 ± 1.93	14.30 ± 1.87	9.64	0.001	P1 0.006 P2 1.00 P3 1.00 P4 0.017 P5 0.011 P6 1.00

Table (3) CMT (µm) of the patients at all-time measures:

Variable	CMT (µm)
Preop.	504.85 ± 109.05
3rd month	341.10 ± 75.35
6th month	322.05 ± 87.40
Test of significance	103.93
P value	<0.001
Post Hoc	P1 <0.001 P2 <0.001 P3 0.271

Table 4: VA (decimal) of the patients at all-time measures

Variable	VA (decimal)
Preop.	0.08 ± 0.05
3rd month	0.3 ± 0.13
6th month	0.35 ± 0.16
Test of significance	87.42
P value	<0.001
Post Hoc	P1 <0.001 P2 <0.001 P3 0.038

Table (5) Correlation between HbA1c and 6th month VA and CMT:

	HbA1c	
	r	P value
6th m VA (decimal)	-0.552	0.339
6th m CMT (µm)	<0.001	0.033

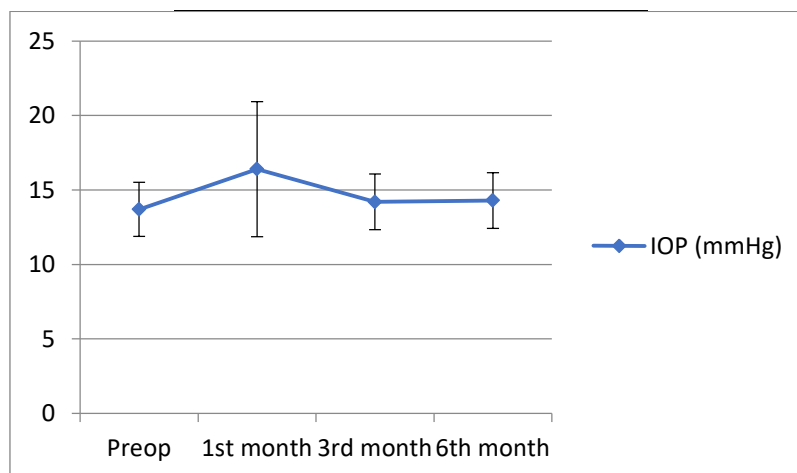


Fig.1: IOP (mmHg) at all time measures

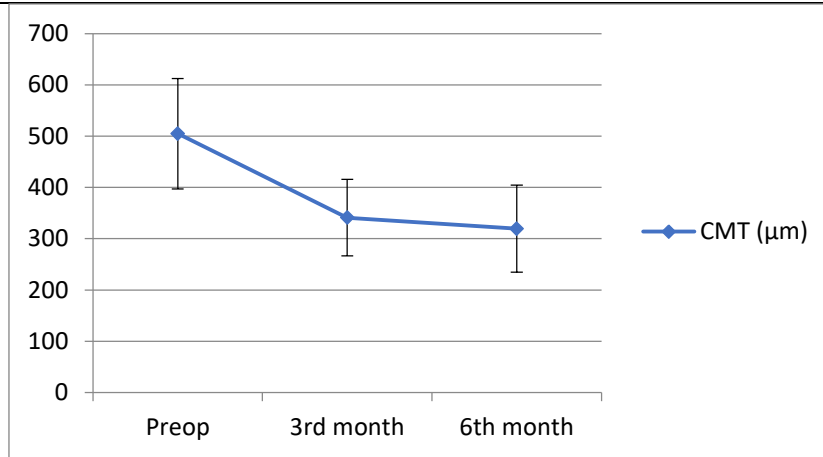


Fig.2: Mean CMT (µm) of the patients at all-time measures

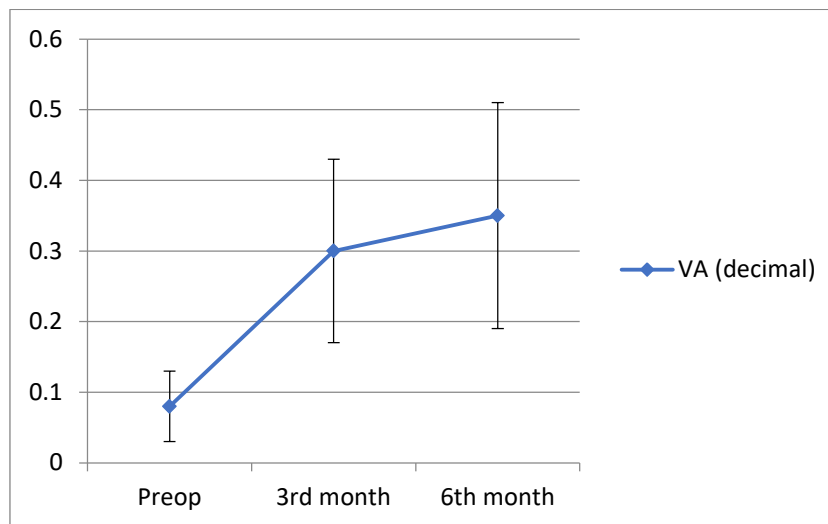


Fig.(3) Mean BCVA (decimal) of the patients at all-time measures

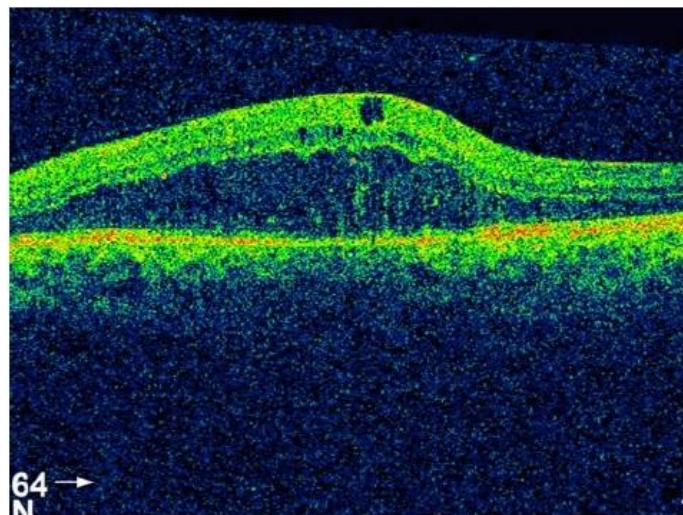


Fig.4: Preoperative OCT macula of a patient in the study with CME 1 week preoperatively with increased macular thickness (607 µm).

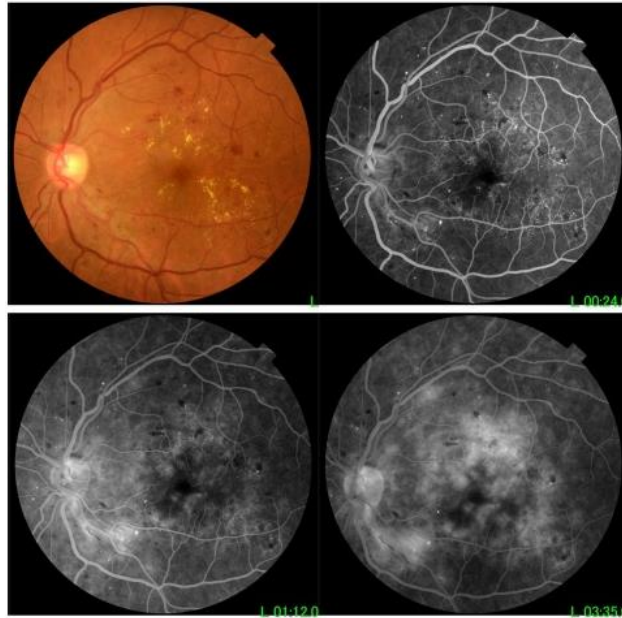


Fig.(5) Preoperative FFA of the same patient 1 week preoperatively.

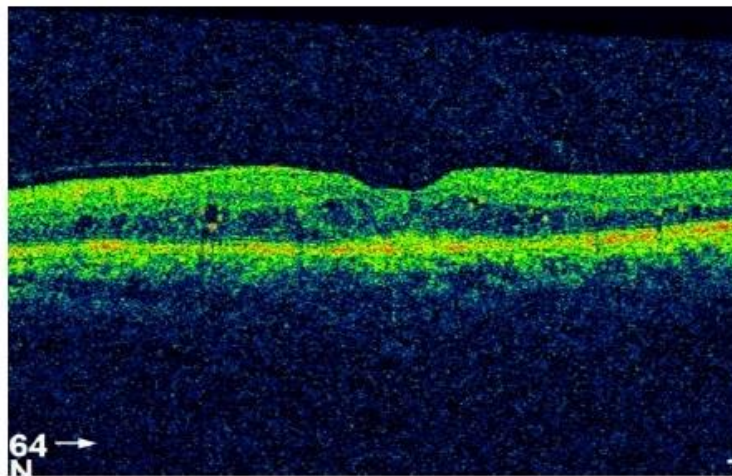


Fig.6: OCT macula of the same patient three months postoperatively shows dramatic resolution of the macular edema to (304 um).

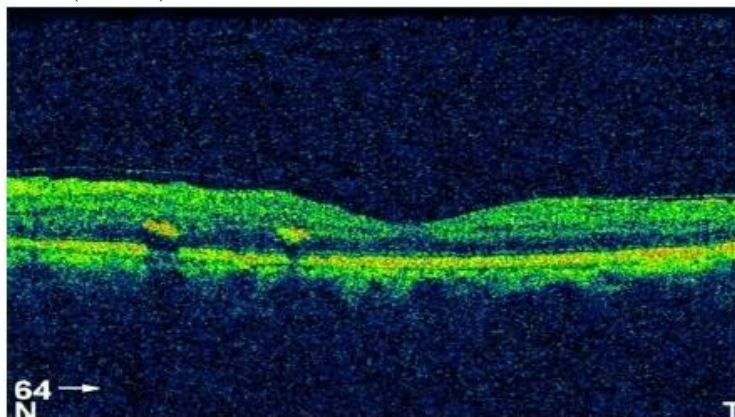


Fig.7: OCT macula of the same patient 6 months post operatively still showing resolution of the macular edema & within normal thickness (225um).

5. Discussion

In patients with CSMO detected preoperatively, treatment with macular laser photocoagulation is recommended at least 12 weeks prior to surgery. However, this may be difficult in patients with significant cataract. Diabetic CSMO refractory to conventional laser treatment methods is also not an uncommon problem. Much of the existing data in the literature suggest that diabetic patients with CSMO at the time of cataract surgery have poorer visual outcomes⁽⁹⁾.

In [10] study, all patients with CSMO at the time of surgery had persistent macular edema at the 1-year follow-up with poorer visual outcome⁽¹⁰⁾. Also, the development of a component of pseudophakic cystoid macular oedema (Irvine–Gass syndrome) is a possible confounding factor and may be more common in diabetic patients undergoing cataract extraction as compared to the incidence in non-diabetics⁽¹¹⁾.

Intravitreal pharmacotherapies have largely replaced photocoagulation for patients with center-involving DME. Corticosteroids are preferable to anti-VEGF agents in selected cases, patients who wish to reduce the number of required injections and in pregnant patients who require treatment of the DME before delivery⁽¹²⁾.

[13] compared the efficacy of the IVTA versus intravitreal bevacizumab (IVB) in the treatment of DME. Results of IVTA group showed significant decrease in CMT when compared with IVB⁽¹³⁾.

[14] studied forty eyes of 20 patients with bilateral diffuse DME. For each patient, 4 mg/0.1 ml IVTA was injected to one eye and 2.5 mg/0.1 ml IVB was injected to the other eye. The effects of injection for diabetic macular edema (DME) were evaluated using BCVA, CMT by OCT and IOP by applanation tonometer. Follow-up was done 1, 4, 8, 12 and 24 weeks after injection. The results showed frequent macular edema recurrences in the eyes treated with bevacizumab compared with the ones treated with triamcinolone acetonide. Triamcinolone acetonide was found to provide more efficient and long-standing effect in terms of reducing CMT compared with the bevacizumab⁽¹⁴⁾.

The present study was conducted on 40 eyes of 32 patients having clinically significant diabetic macular edema and immature senile cataract treated by combined phacoemulsification and intravitreal injection of 4mg triamcinolone acetonide (IVTA) to compare functional and central thickness changes of the macula for 6 months.

All eyes included in the study had uncomplicated phacoemulsification with intact posterior capsule, intact zonules and absence of vitreous herniation with intrabagal PCIOL implantation.

Intravitreal injection of TA has been associated with various potential complications, elevation of IOP is the most common. In our study, the mean preoperative IOP was 13.70 ± 1.82 (mmHg). One month after injection, the mean IOP significantly elevated to 16.40 ± 4.53 (mmHg), however, at the 3rd month, it was significantly reduced to 14.30 ± 1.93 (mmHg) to be non-significant from the preoperative level. The level of IOP continued to be stable at 14.30 ± 1.87 (mmHg) till the 6th postoperative month. 6 patients (15%) in our study developed elevated IOP, from a baseline mean of 14 ± 2 mmHg to a mean of 27.33 ± 2.52 mmHg one month after injection, which was controlled with topical antiglaucomatous medications and only one patient needed to continue on antiglaucoma medications after the end of the study.

The most serious potential complication of intravitreal TA injection is the development of endophthalmitis. [15] reported several cases of endophthalmitis after intravitreal TA injection. It was suggested that diabetes due to its association with immunosuppression, may be a risk factor for endophthalmitis after intravitreal TA injections⁽¹⁵⁾. None of our patients in this study developed this serious complication postoperatively.

Regarding morphological analysis in our study, central macular thickness (CMT) as measured by OCT decreased from an initial pretreatment mean of 504.85 ± 109.05 μm to a mean of 341.10 ± 75.35 μm after 3 month, then a mean of 322.05 ± 87.40 at the 6th month. the central macular oedema of all eyes showed significant reduction in CMT up to the 6th month postoperatively except in 12 eyes (30%). 10 eyes of those 12 eyes showed reduction of CMT at the 3rd month but CMT increased again at the 6th month although not reaching preoperative level. 2 eyes in the study showed refractory oedema with insignificant reduction of CMT throughout the study. Recurrence of macular oedema following IVTA injection is not uncommon. In total, 37.5% of eyes were found to have recurrence of macular oedema 6 months after IVTA injection for refractory diabetic macular oedema in the study by [16]

Regarding changes in best corrected visual acuity (BCVA) in the present study, Mean BCVA was 0.08 ± 0.05 at baseline and improved to a mean of 0.3 ± 0.13 after 3 months, then to a mean of 0.35 ± 0.16 at the

6th month after surgery. In our study, 24 eyes (60%) Of the 40 eyes, had significant improvement in BCVA by more than 2 snellen lines at 6 months. 14 eyes had improvement in BCVA less than 2 snellen lines at 6 months(10 eyes showed BCVA deterioration at the 6th month when CMT increased at the end of the study and 4 eyes with significant CMT reduction but minimal improvement in BCVA). 2 eyes with refractory macular oedema showed no improvement in BCVA throughout the study.

[17] studied 19 eyes of 15 diabetic patients with cataract and CSMO. Patients underwent phacoemulsification and intraocular lens implantation with 4 mg IVTA injection at completion of surgery. The effects of injection for diabetic macular edema (DME) were evaluated using BCVA, CMT by OCT and IOP by applanation tonometer. Patients were followed up on day 1, then weekly for 1 month, and thereafter monthly until 6 months postoperatively. In total, 17 eyes completed 6 months of follow-up and results showed 58.8% improvement in BCVA of ≥ 2 lines, with statistically significant improvement in mean Snellen BCVA of 2.4 lines at 6 months. The mean CMT decreased from a baseline of 449 μm to a minimum of 321 \pm 148 μm achieved at 2 months, with statistically significant reduction at all postoperative time intervals until 6 months. Of 17 eyes, 4 (23.5%) developed transiently elevated intraocular pressure that normalised by 6 months in all but one patient. No injection- or surgery-related complications were encountered⁽¹⁷⁾.

[18] studied 41 eyes of 36 diabetic patients with cataract and coexisting clinically significant macular edema (CSMO). After PHACO and IVTA injection eyes were divided into two groups: the laser and IVTA group (Group 1) and only IVTA group (Group 2). Results showed that postoperative BCVA was significantly higher than the initial BCVA during the follow-up period in both groups. The BCVA 6 months after surgery was significantly higher in group 1 than in group 2. There was no statistically significant difference between both groups in mean CMT preoperatively and 2nd week, 2nd month and 3rd month after surgery. The mean CMT 6 months after surgery was statistically significantly lower in group 1 than in group 2⁽¹⁸⁾.

The true extent of the contribution of clearer media after cataract extraction in improving visual acuity of those patients with diabetic CSMO is difficult to ascertain, as we did not have a control group in our study comparing diabetic patients with CSMO who

underwent phacoemulsification without IVTA. Nevertheless, anatomical improvement in macular oedema has previously been shown to be highly correlated with functional improvement in visual acuity in other studies using IVTA alone⁽¹³⁾⁽¹⁴⁾.

6. conclusion

Phacoemulsification with injection of intravitreal TA may be performed safely in DME patients without risk of significant complications such as persistent IOP rise and endophthalmitis. Moreover, 70% of eyes had statistically significant CMT reduction with 60% significant improvement in BCVA postoperatively, which was maintained 6 months of follow-up. However, further multicenter studies on a larger sample size are needed to assess the long-term efficacy and the need for retreatment or using IVTA as adjuvant to other agents.

Conflict of interest

The authors have no conflict of interest to declare.

7. References

- [1] J.Ding, T.Y.Wong, Current Epidemiology of Diabetic Retinopathy and Diabetic Macular Edema. Current Diabetes Reports. August;Vol.12,pp.346-354. 2012
- [2] B.Wiostko, T.Y.Wong, R.Simó, Vascular endothelial growth factor and diabetic complications. Progress in Retinal and Eye Research, vol.27,pp.608–621 2008.
- [3] T.Murakami, N.Yoshimura, Structural Changes in Individual Retinal Layers in Diabetic Macular Edema. Journal of Diabetes Research; Article, vol.27,pp.608–621 2013.
- [4] M.Sahin, A.K.Cingü, N.Gözüm, Evaluation of cystoid macular edema using optical coherence tomography and fundus autofluorescence after uncomplicated phacoemulsification surgery. Journal of Ophthalmology, Volume Article ID, vol.27,pp.608–621 2013
- [5] J.Liu, R.E.Jones, J.Zhao, Influence of Uncomplicated Phacoemulsification on Central Macular Thickness in Diabetic Patients: A Meta-Analysis. PLoS ONE; Vol.10,pp.12-343. 2015
- [6] M.W Stewart, Corticosteroid Use for Diabetic Macular Edema: Old Fad or New Trend? Current Diabetes Reports, August;Vol.12,pp.364-375 2012
- [7] Campos António, Beselga.Diana, Mendes.Sílvia, Journal of Ocular Pharmacology and Therapeutics. November, Vol.30,pp. 717-728. 2014

- [8] M.S.Habib , P.S.Cannon , D.H.Steel ,The combination of intravitreal triamcinolone and phacoemulsification surgery in patients with diabeticfoveal oedema. BMC Ophthalmology ,Vol.10,pp.12-303,2005
- [9] Royal.College of Ophthalmologists, The Royal College of Ophthalmologists Published Guidelines: Cataract Surgery Guidelines ; Vol.10,pp.11-3332001.
- [10]J.G.Dowler, Kulwant SS, Hykin.PG and Hamilton.PA, The natural history of macular edema after cataract surgery in diabetes. Ophthalmology; 106: 663–668. 1999
- [11]S.Ray , D.J, D’Amico, Pseudophakic cystoid macular edema. Semin Ophthalmol,Vol.17: ,pp.167–1802002.
- [12]S.G. Schwartz, I.U.Scott , M.W.Stewart,Update on corticosteroids for diabetic macular edema. Clinical Ophthalmology (Auckland, NZ),Vol.10,pp1723-1730. 2016
- [13]X.L.Zhang, J.Chen , R.J.Zhang , Intravitreal triamcinolone versus intervitreal bevacizumab for diabetic macular edema: a meta-analysis. Int J Ophthalmol,Vol.6,pp546–552, 2013
- [14]S.Aksoy, G.Yilmaz , I .Akkoyun, Comparison of intravitreal bevacizumab and triamcinolone acetone therapies for diffuse diabetic macular edema. International Journal of Ophthalmology,Vol. 8,pp.550-555,2015
- [15]D.M.Moshfeghi, P.K.Kaiser, I.U.Scott, Acute endophthalmitis following intravitreal triamcinolone acetone injection. Am J Ophthalmol,Vol. 136,pp. 791–796, 2003
- [16]A.Martidis, J.Duker, P.Greenberg, Intravitreal triamcinolone for refractory diabetic macular edema: Ophthalmology,Vol.109, pp.920-927, 2002
- [17]D.S.Lam, C.K.Chan , S.Mohamed, Phacoemulsification with intravitreal triamcinolone in patients with cataract and coexisting diabetic macular oedema: a 6-month prospective pilot study. Eye (Lond) 2005; 19:885–890.
- [18]O.R.Ozgun, Y. Ozkurt, Z.Kulekci , The combination of phacoemulsification surgery and intravitreal triamcinolone injection in patients with cataract and diabetic macular edema. Saudi Journal of Ophthalmology Volume 30, Issue 1, January–March, Pages,Vol.11,pp.33-38,2016